

# LARGE CHOLEDOCHOCELE ASSOCIATED WITH STONES: A RARE PRESENTATION OF CHOLEDOCHAL CYSTS

*Coledococele Volumosa Associada a Cálculos: Uma Apresentação Rara de Cistos de Colédoco*

Angélica Maria **LUCCHESI**, Paula Suzin **TRUBIAN**, Antonio Carlos **ZANETTINI**, Tiago Cataldo **BREITENBACH**

**Como citar este artigo:** Lucchese AM, Trubian PS, Zanettini AC, Breitenbach TC. Large choledococele associated with stones: a rare presentation of choledochal cysts. ABCExpress. 2018;1:e11. DOI: /10.17982/2359-273720180001e11

Department of General Surgery. Hospital Nossa Senhora do Pompéia, Caxias do Sul, RS, Brazil

**DESCRITORES** - Cisto de colédoco, Cálculos Biliares, Colectomia, Colangiocarcinoma

**Correspondência:**  
Angélica Maria Lucchese  
Email: angelica\_luc@hotmail.com

**HEADINGS** - Choledochal cyst, Gallstones, Cholecystectomy, Cholangiocarcinoma.

## INTRODUCTION

Choledochal cysts are a rare and abnormal dilatation of the intra- and extra-hepatic bile ducts<sup>1</sup>. The cysts are classified into five types according to Todani's Classification<sup>2</sup>. Type III cysts or choledococeles, are a dilatation of the intramural common bile duct, within the wall of the duodenum, and account for less than 5% of all reported cysts<sup>3</sup>.

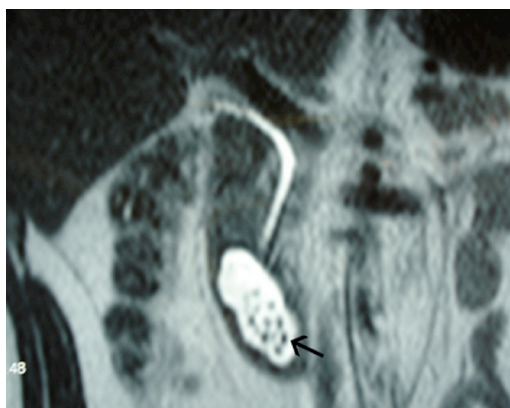
The present paper reports a case of a large choledococele that is associated with gallstones within the cyst.

## CASE REPORT

A 45-year-old male patient had a history of abdominal pain in the right upper quadrant, with progressive worsening in intensity and decreasing intervals for approximately two years. Besides eventual vomiting, there were no other symptoms or previous pathologies, and laboratory exams were normal. He underwent cholecystectomy at another institution five months before admission to our service. The symptoms, however, remained the same after the procedure.

A computerized tomography scan was performed and revealed a cyst formation along the wall of the second portion of the duodenum measuring 4.6x2.7 cm. The formation had well-defined contours and contained small nodular formations (sizes between 3 and 7mm), suggesting the presence of gallstones. This cystic formation appeared to connect with the common bile duct. Intrahepatic bile ducts were not dilated.

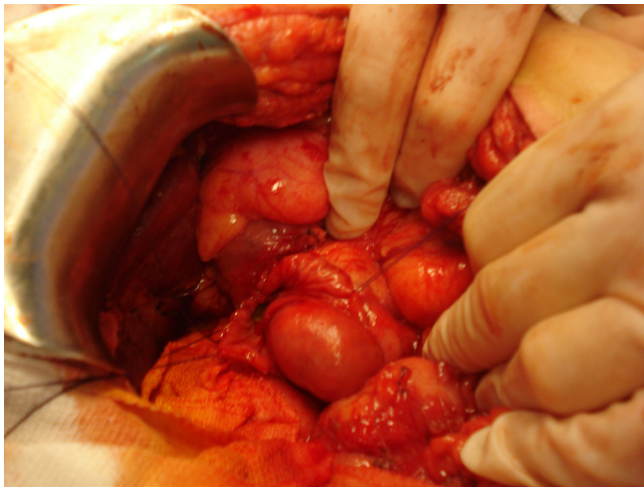
An endoscopy exam revealed a protrusion in the second portion of the duodenum. Magnetic resonance cholangiopancreatography was conducted and showed cystic dilatation of the distal common bile duct in the papilla region, measuring 5.3x2.0 cm. The cyst contained approximately 20 small stones and was protruding into the duodenum, causing reduction of the diameter of its light. The remainder of the common bile duct was not altered (Figure 1).



**FIGURE 1** - Cystic dilatation of the distal common bile duct in the papilla region

Laparotomy was then performed. After conducting choledocotomy and duodenotomy, we visualized a protrusion on the duodenal wall that was approximately 5 cm (Figure 2).

The cyst was opened and 20 small calculi were removed. Most of the cyst wall was resected, preserving the area of the papilla. Marsupialization of the edges followed by duodenorrhaphy were also performed.



**FIGURE 2** - Protrusion on the duodenal wall that was approximately 5 cm

The patient had an uneventful postoperative course and was discharged seven days after surgery, asymptomatic. Another magnetic resonance cholangiopancreatography was conducted one month post-surgery and showed unrestricted bile passage without remnants of cystic dilatation.

## DISCUSSION

The precise etiology of choledochal cysts is not yet clear. The most accepted theory hypothesizes that a defect at the junction of the biliary and pancreatic ducts results in a single channel that is longer than usual. The junction occurs outside of the duodenum, allowing constant contact of the bile duct mucosa with pancreatic juice, causing irritation and local inflammation. This reflux of pancreatic fluid results in the weakening of the biliary tree wall and cystic degeneration.<sup>4</sup>

Some authors argue that choledochoceles represent a different disease entity<sup>5</sup>, because, as opposed to other choledochal cysts, it is more rare, presents with a later onset (average age 51 years), has no gender predilection, and is less related to anomalous pancreatobiliary duct union<sup>3</sup>. The

complications of choledochoceles include choledocholithiasis, cholangitis and pancreatitis<sup>6</sup>.

The presence of gallstones within the cyst has been reported in some cases of choledochal cysts and is associated with bile stasis.<sup>4,7</sup> Also, patients with choledochal cysts type III are more likely to have undergone a previous cholecystectomy at the time of diagnosis<sup>1</sup>.

Patients with choledochal cysts have an approximately 20 to 30% increased risk of developing cholangiocarcinoma. Therefore, the indication of complete removal of cysts is well established in almost all types of cysts. The surgical management of type III cysts is an exception to this rule for multiple reasons: the risk of malignancy involving choledochoceles is very low compared to the other types of choledochal cysts<sup>6</sup> and second a complete resection usually involves pancreatoduodenectomy, a major surgery with potential complications.

The most commonly performed surgical procedure for treating choledochoceles is transduodenal excision of the cyst wall, with or without sphincteroplasty<sup>3</sup>, especially for large choledochoceles with associated complications such as pancreatitis<sup>1</sup>. Depending on the suspicion of neoplasia, pancreatoduodenectomy may be indicated<sup>3</sup>. Endoscopic sphincterectomy has become the standard of care in many centers for small choledochoceles, and has achieved great results<sup>5,8</sup>. The rarity of this disease makes the development of a unified management approach difficult.

## REFERENCES

1. K.C. Soares, D.J. Arnaoutakis, I. Kamel, N. Rastegar, R. Anders, S. Maithel, et al., Choledochal cysts: presentation, clinical differentiation, and management, *J Am Coll Surg.* 219 (2014) 1167-1180.
2. T. Todani, Y. Watanabe, M. Narusue, K. Tabuchi, K. Okajima, Congenital bile duct cysts: Classification, operative procedures, and review of thirty-seven cases including cancer arising from choledochal cyst, *Am J Surg.* 134 (1977) 263-269.
3. R. Law, M. Topazian, Diagnosis and treatment of choledochoceles, *Clin Gastroenterol Hepatol.* 12 (2014) 196-203.
4. M. Mesleh, D.J. Deziel, Bile duct cysts, *Surg Clin North Am.* 88 (2008) 1369-1384, x.
5. K.M. Ziegler, H.A. Pitt, N.J. Zyromski, A. Chauhan, S. Sherman, D. Moffatt, et al., Choledochoceles: are they choledochal cysts?, *Ann Surg.* 252 (2010) 683-690.
6. L.Zhu, H.Zeng, Y.X.Chen, N.H.Lu, Endoscopic management of choledochoceles complicated with choledocholithiasis and pancreatitis in an old patient, *Aging Clin Exp Res.* (2014).
7. S.O. Hwang, T.H. Lee, S.H. Bae, D.J. Han, H.M. Lee, S.-H. Park, et al., Diverticular Choledochal Cyst with a Large Impacted Stone Masquerading as Mirizzi's Syndrome, *Case Reports in Gastroenterology.* 7 (2013) 164-168.
8. M. A. Rodrigues, A.V. Souza, F. Falcone et al. Endoscopic treatment of choledochal cyst type III. *ABCD. Arq Bras Cir Dig.* (2008) 139-41.